Neuroimaging 101: MRI

Chris Borgman, OD, FAAO
Associate Professor
Memphis, TN

SOUTHERN COLLEGE OF OPTOMETRY

COPE Disclosures:

- I do not have any relevant financial relationships to disclose.
- The content and format of this course is presented without commercial bias and does not claim superiority of any commercial product or service.

Before we start….phew!

https://4thgeneration.energy/down-the-rabbit-hole-part-ii/

Let's see just how far this neuroimaging rabbit hole goes; shall we?

Ground Rules…

- References/sources available if you want them…
- I'm not perfect…
- Please email me with questions:
  - cborgman@sco.edu

Neuroimaging Topics to Cover

- Main Types of Neuroimaging:
  - ~~Computed Tomography (CT)~~
  - ~~Computed Tomography Angiography (CTA)~~
  - ~~Computed Tomography Venography (CTV)~~
  - Magnetic Resonance Imaging (MRI)
  - ~~Magnetic Resonance Imaging Angiography (MRA)~~
  - ~~Magnetic Resonance Imaging Venography (MRV)~~

Basic Radiology Information for OD's

- Left vs. right in radiology
  - Worm's eye view

https://serc.carleton.edu/details/images/193361.html

https://www.sironacc.com/product/patient-support-external-scan-track-system-with-scan-bands/

Assumed position when "reading" scans



Radiology Planes To Know

- Coronal
- Sagittal
- Axial

https://www.ipfradiologyrounds.com/hrct-primer/image-reconstruction/

Side Thoughts…
Pregnancy and neuroimaging?

- CT = not safe during pregnancy due to radiation
- MRI = very safe during pregnancy (no contrast though)

- When in doubt, consult radiologist and/or patient's OB/GYN

Magnetic Resonance Imaging

Want to learn more about MRI?

- I highly recommend this website!
- www.mriquestions.com
- *"There is no charge for using this site; it is my gift back to the MRI community that has been so good to me." --Dr. Allen Elster*

- **Allen D. Elster, MD FACR**
  Mallinckrodt Institute of Radiology
  Washington University School of Medicine
  St. Louis, MO

  Chair Emeritus
  Wake Forest University School of Medicine
  Winston-Salem, NC

What is MRI actually imaging???

- Hydrocarbons (ie. fat)
- Water

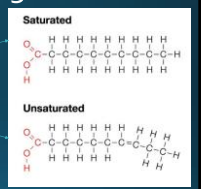

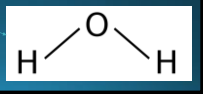

- Bottom Line:
  - MRI images HYDROGEN!

How does MRI work again?

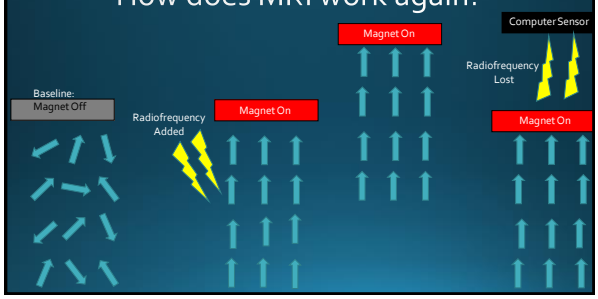

Term to know…

- Tesla (T)
  - Earth's magnetic field = ~0.5 Gauss
    - Fridge magnet = 100 Gauss = 200 times earth's magnetic field
    - Junkyard electromagnet = 10,000 Gauss (1 T)
  - 1 T = 10,000 Gauss
  - 1.5 Tesla is standard on majority of MRI machines
    - 15,000 Gauss = 30,000 times earth's magnetic field
  - 3.0 Tesla becoming more popular
    - 30,000 Gauss = 60,000 times earth's magnetic field
  - The higher the Tesla, the better the sensitivity/resolution of the MRI

www.mriquestions.com

Extremely strong magnetism!

https://www.pinterest.com/gabewh/mri-fail/

https://www.pinterest.com/pin/800585271230592687 21/

https://gifer.com/en/2qfc/mri

What does a standard head/brain MRI consist of?

- 200-300 scans
  - Sometimes 400-500 scans…
- 5 mm thickness
- Entire MRI sequence can last 30-60 minutes in general
  - Sometimes longer depending on protocol used
- Takes me about 7-10 minutes to review images on my own

What does a standard head/brain MRI consist of?

Standard MRI Consists Of:

- (-)contrast
- Standard Slices: 5 mm
- Axial, coronal, sagittal planes
- Pulse Sequences
  - T1
  - T2
  - FLAIR
  - DWI
  - ADC
  - GRE/SWI

Add-Ons To Specify:

- (+)contrast
- Fat suppression/STIR
- Thin slices: 1-3 mm
- Emphasize location
  - What are you looking for based on your exam?
- Sagittal views are sometimes weirdly omitted, if needed consider specifying this specifically…

MRI

Remember, language of CT = density!

- Language of MRI = **Intensity!**
- Soft tissue>>>>bone
  - Ideal for brain anatomy related to eyes
- No known harmful effects to biologic tissues
  - No ionizing radiation as with CT
- Careful with implanted metal objects!!!
  - Pacemakers, stents, metallic foreign bodies, etc.
- 10% patients suffer from claustrophobia
- MRI clarity is very susceptible to movement!
  - Sedation or anesthesia warranted sometimes
    - Kids, mentally challenged/disabled patients, etc.
- 1.5 Tesla is standard strength nowadays
  - 3.0 T becoming more popular though → better resolution

https://gifer.com/en/gifq/mri

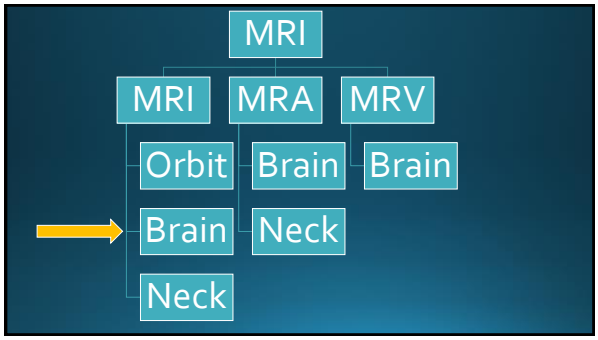

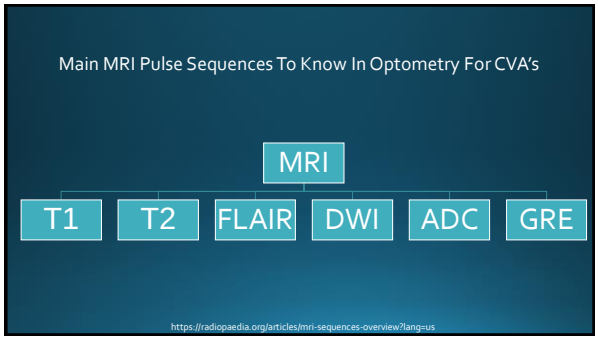

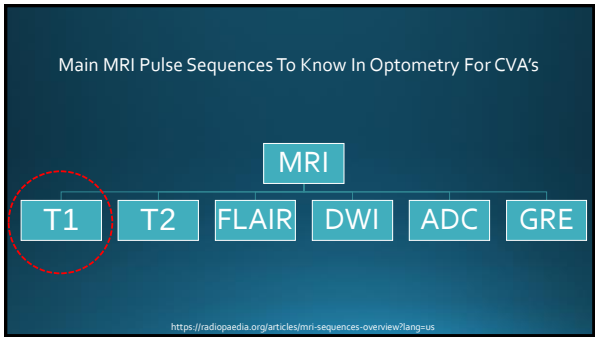

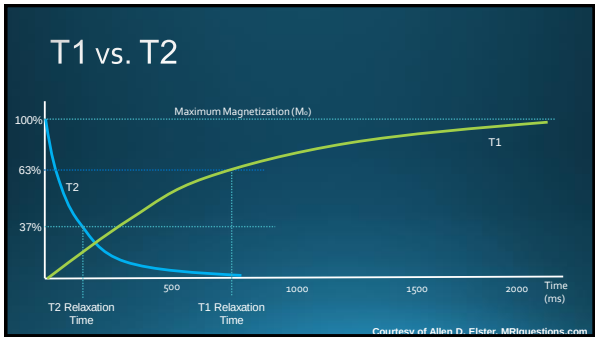

- Water and fat are opposite signals!
- T1: water is dark, fat is bright
- T2: water is bright, fat is dark

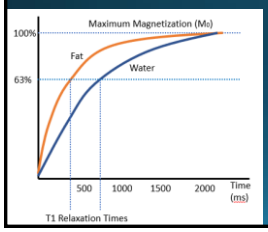

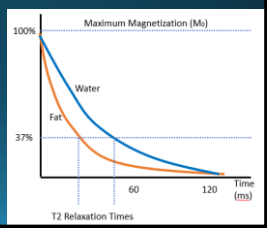

- Water and fat are opposite signals!
- T1: water is dark, fat is bright
- T2: water is bright, fat is dark

T1

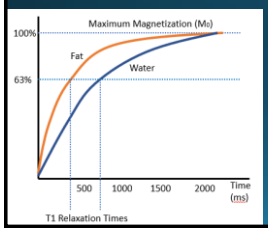

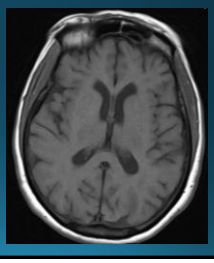

T1

- T1= "time 1" based on previous graphs
- Signal at 63% growth time compared to baseline

- Fat is bright (aka: hyperintense)
- Water is dark (aka: hypointense)
- Acute blood is bright (aka: hyperintense)

- Best uses:
- Anatomic detail
  - Most closely approximates true histological anatomy (overly simplified though)
- Acute hemorrhage
- Vascular changes with contrast
- Disruption of BBB with contrast

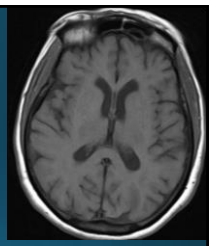

T1 with contrast (Gadolinium)

- Gadolinium is a "paramagnetic" molecule
- Paramagnetic
  - Defn: intrinsic property of certain materials to become temporarily magnetized when placed in an external magnetic field.
  - Gadolinium is used in MRI = contrast
  - MOA: Contrast shortens T1 and T2 relaxation times
    - Effect is negligible on T2 though in general
    - Best effect with T1 weighted image
  - Contrast identifies breakdown of blood/brain barrier
    - Best uses → tumors, inflammation (ie. acute demyelination)
    - Not as helpful in acute strokes

www.mriquestions.com

Courtesy of Allen D. Elster, MRIquestions.com

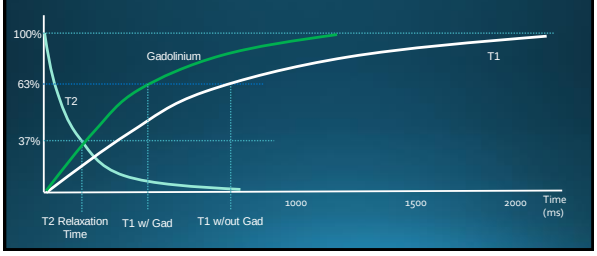

Papilledema Example

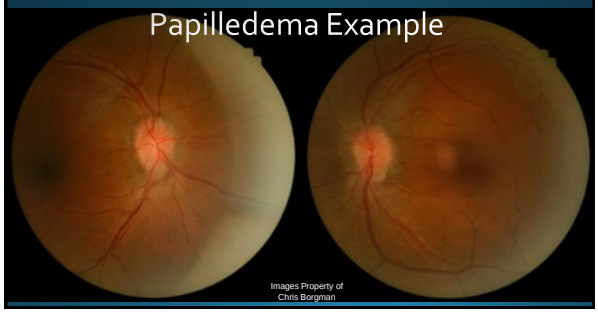

Images Property of Chris Borgman

MRI

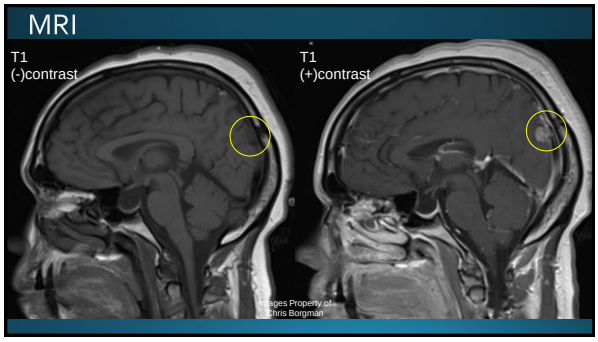

Images Property of Chris Borgman

MRI

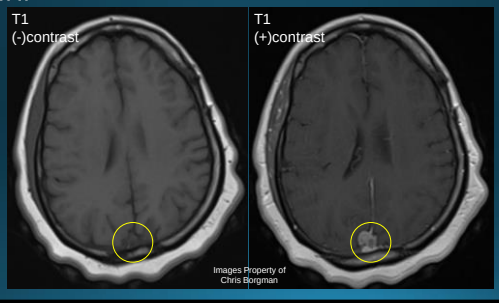

Images Property of Chris Borgman

Pituitary Adenoma Example

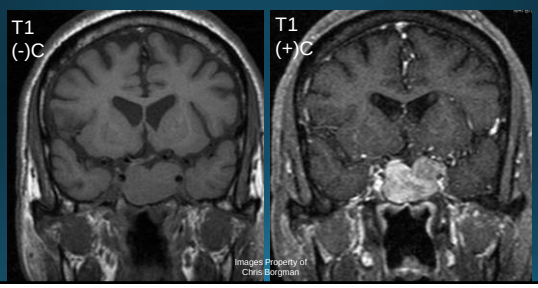

Different Patient: Benefits of Contrast

- Colon cancer metastasis

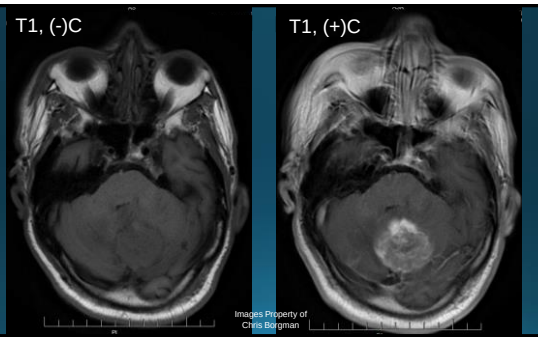

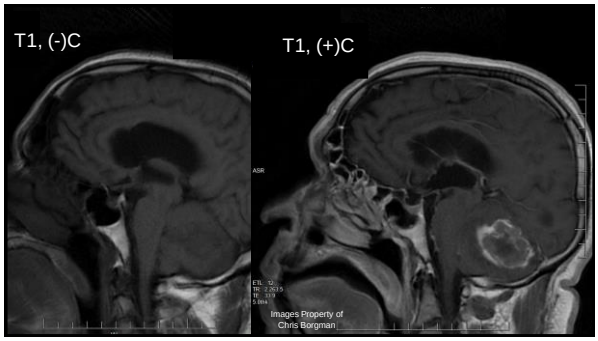

Main MRI Pulse Sequences To Know In Optometry For CVA's

https://radiopaedia.org/articles/mri-sequences-overview?lang=us

- Water and fat are opposite signals!
- T1: water is dark, fat is bright
- T2: water is bright, fat is dark

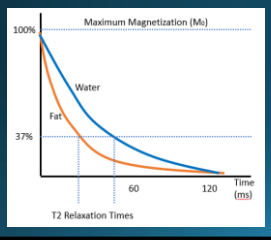

T2

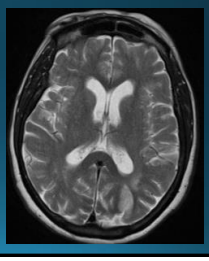

T2

- T2= "time 2" based on previous graphs
- Signal at 37% decay time

- Opposite of T1
  - Fat is dark
  - Water is bright
  - Flow is dark in blood vessels (flow void)

- Best uses:
- Anatomic details (CSF spaces)
- Most lesions!
  - Why? Because most lesions result in excess H20!
- Cannot distinguish lesions from CSF when very near CSF spaces

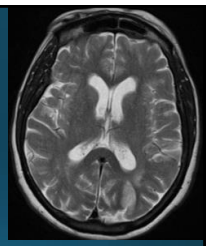

Courtesy of Allen D. Elster, MRIquestions.com

Gadolinium (Contrast) effect: T1>>>T2

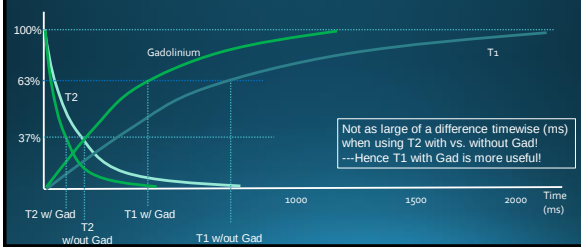

Main MRI Pulse Sequences To Know In Optometry For CVA's

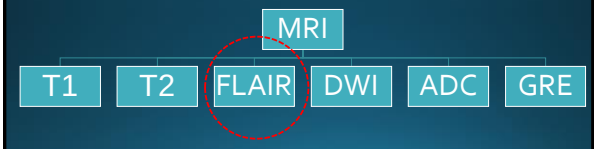

https://radiopaedia.org/articles/mri-sequences-overview?lang=us

T2 FLAIR

- "Fluid Attenuation Inversion Recovery"

- FLAIR = T2 image with suppression of CSF signal (ie. CSF is dark)
- Non-free flowing water is bright
- Fat is dark

- Best uses:
  - Same as T2
  - Delineation of lesions (ie. MS) near ventricles
  - Edema
  - Grey-white differentiation

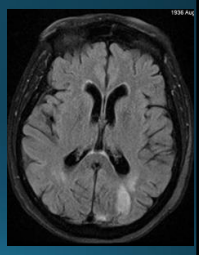

www.mriquestions.com

T2 vs. T2 FLAIR

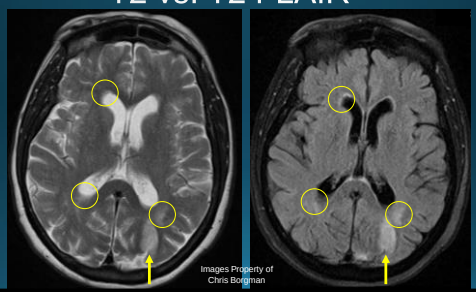

Images Property of Chris Bergman

Main MRI Pulse Sequences To Know In Optometry For CVA's

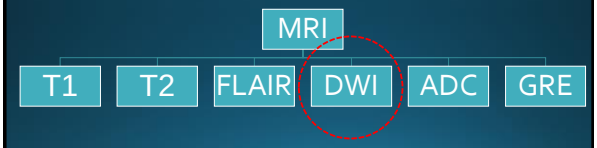

https://radiopaedia.org/articles/mri-sequences-overview?lang=us

DWI

- Diffusion Weighted Imaging
  - Strong T2 component
- Stroke services favorite sequence!
- The only sequence to identify acute stroke within minutes of CVA
- Acquisition time is only a few minutes compared to other MRI sequences

- Fluid restriction is bright (cytotoxic edema)
- Must correlate with ADC
  - Fluid restriction is dark
  - Rule out "T2 Shine Through"
- Best uses:
  - *Acute Ischemia
  - Abscess
  - Seizures

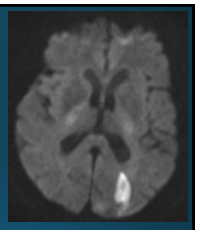

www.mriquestions.com

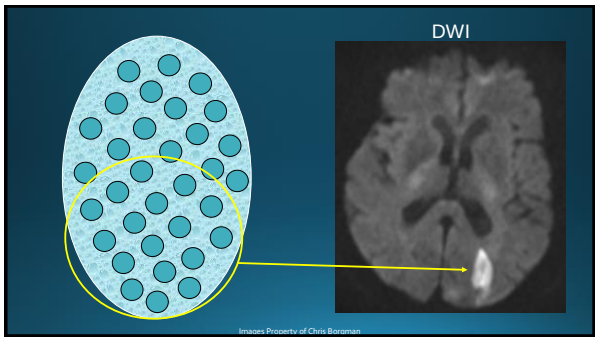

Main MRI Pulse Sequences To Know In Optometry For CVA's

https://radiopaedia.org/articles/mri-sequences-overview?lang=us

ADC

- Apparent Diffusion Coefficient
- Estimates avg diffusion rates in tissues being studied
  - ie. compare to the standard "norm"
- Used to clarify abnormalities seen on the DWI images
- Inversely proportional to DWI
  - High diffusion = brighter
  - Low diffusion = dark
    - acute ischemic strokes!

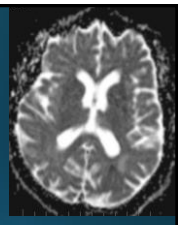

www.mriquestions.com

Signal evolution of DWI and ADC over time in stroke...

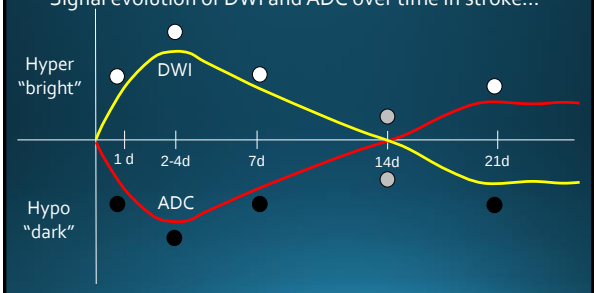

Diffusion	DWI vs. ADC		Examples
Diffusion Restriction	○	●	• Cytotoxic edema (acute ischemia) • Acute demyelination
Increased Diffusion	●	○	• Cerebrospinal fluid (CSF)
T2 Shine-Through	○	○	• Vasogenic edema

DWI ADC

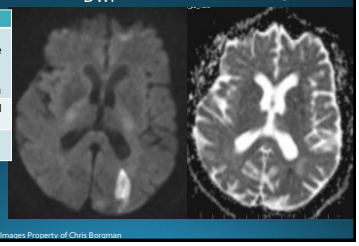

What is timeline of this stroke?

Acute! 1 day old stroke

Images Property of Chris Boroman

Diffusion	DWI vs. ADC		Examples
Diffusion Restriction	○	●	• Cytotoxic edema (acute ischemia) • Acute demyelination
Increased Diffusion	●	○	• Cerebrospinal fluid (CSF)
T2 Shine-Through	○	○	• Vasogenic edema

DWI ADC

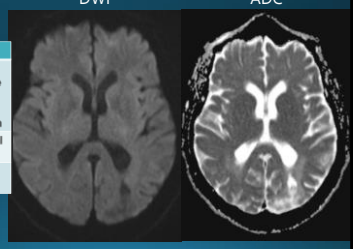

What is timeline of this stroke?

Chronic! 6 months since CVA

Images Property of Chris Borgman

Main MRI Pulse Sequences To Know In Optometry For CVA's

MRI

T1 T2 FLAIR DWI ADC GRE

https://radiopaedia.org/articles/mri-sequences-overview?lang=us

GRE

Images Property of Chris Borgman

- Gradient Echo (aka: T2-Star)
- Original sequence
  - Now being largely replaced by susceptibility weighted imaging (SWI) sequences which are more sensitive
- Can help identify paramagnetic metals in brain
- *Blood (hemosiderin)
- *Calcium
- Other metals (ie. copper in Wilson's disease)
- Best uses:
  - *Early hemorrhage
  - *Old hemorrhage from hemosiderin
  - Calcium deposits

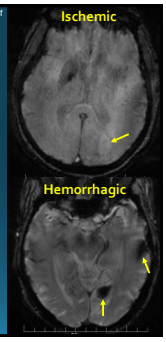

www.mriquestions.com

SWI

- Susceptibility Weighted Imaging (SWI)
- Successor to GRE → touted as more sensitive than GRE
- GRE and SWI are used the same way!
- Mainly used for:
  - +/- hemorrhage
  - calcifications
- Many confusing acronyms based on manufacturer…
  - SWI
  - PADRE
  - SWAN

www.mriquestions.com

GRE/SWI/T2 Star – Calcium example

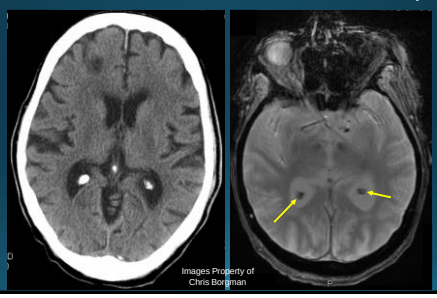

Images Property of Chris Borgman

Quick Review: Stroke Diagnosis/Detection

- Computed tomography (CT/CTA)
  - Can confirm the diagnosis of stroke and tell whether the stroke is caused by ischemia/hemorrhage in the brain
  - Pro: cheaper, fast, metal imaging, bone detail, 2D/3D imaging
  - Con: poorer soft tissue detail, radiation exposure, pregnancy use
- Magnetic Resonance Imaging (MRI/MRA/MRV)
  - Identify and further localize the site of the stroke and find the source
  - Pro: very safe, soft tissue imaging, no radiation, 2D/3D imaging, pregnancy use
  - Con: $$$, no metal imaging, poor bone detail, movement artifacts, prolonged acquisition time

The Borgman MRI CVA Approach: Where I Start…

1. Where do you expect stroke damage to be based on your exam?
2. "12 Feet Down And Gone" mnemonic
   1. **T1**
      - Hyper vs. Hypo
   2. **T2**
      - Hyper vs. Hypo
   3. **T2 FLAIR**
      - Hyper vs. Hypo
   4. **DWI**
      - Hyper vs. Hypo
   5. **ADC**
      - Hyper vs. Hypo
   6. **GRE**
      - Iso vs. Hypo

https://www.campaignasia.com/article/down-the-covid-hole-

Case #1

Case History

- 65 yo WF
- CC: "my vision seems like it's changed after my stroke"
- HPI: CVA x 2 years earlier, left side of vision more than right side
- POH: unremarkable OU
- PMH: HTN, T2DM
- Med: lisinopril, metformin, Januvia, insulin
- Allergies: NKDA

Exam:

- VA cc: 20/20- OD, 20/25+2 OS
- Pupils: PERRL, (-)APD
- CVF: right inf depression OU?
- EOM: FROM OU
- Aseg: 1+ NS OU
- Pseg: normal, see photos
- IOP: 12 OD, 12 OS

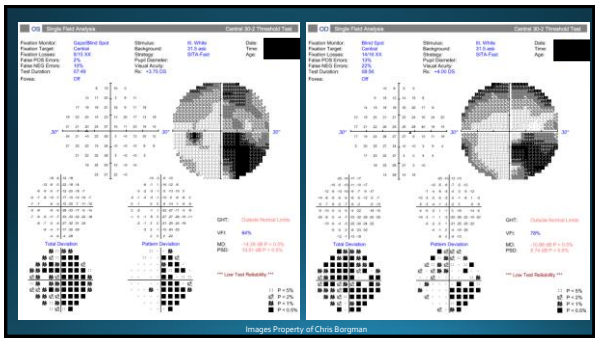

Images Property of Chris Borgman

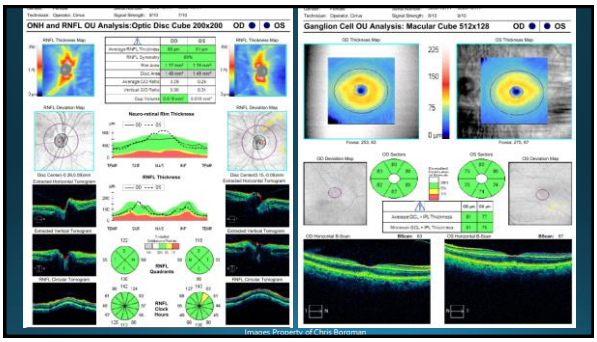

Images Property of Chris Borgman

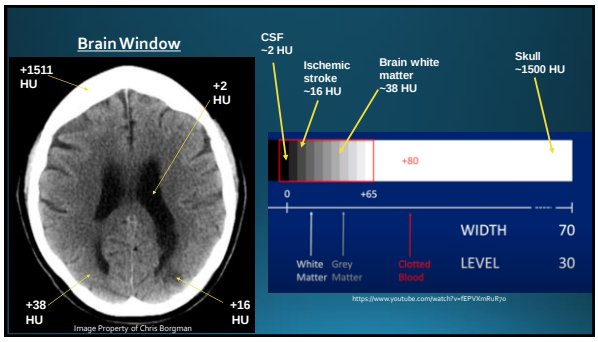

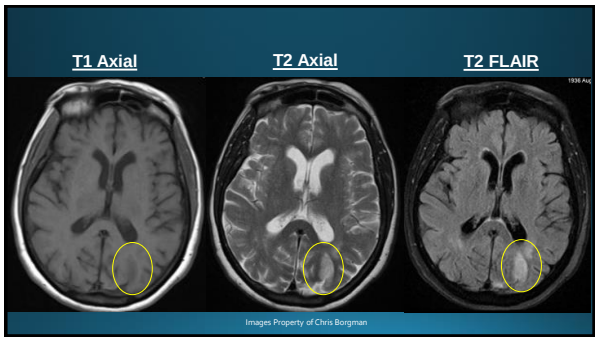

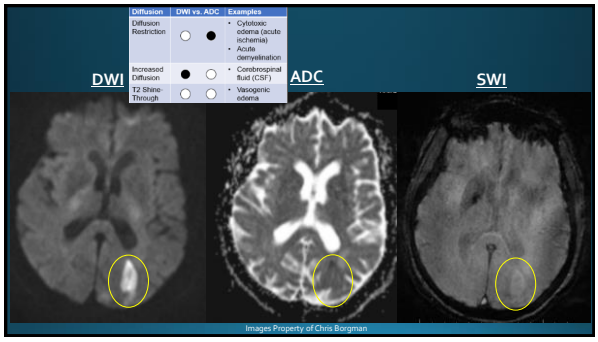

Diffusion	DWI	ADC	Examples
Diffusion Restriction	○	●	• Cytotoxic edema (acute ischemia) • Acute demyelination
Increased Diffusion	●	○	• Cerebrospinal fluid (CSF)
T2 Shine-Through	○	○	• Vasogenic edema

Case #2

Case History

- 65 yo AAM
- CC: "my vision seems like it's changed after my stroke"
- HPI: CVA x 2 years earlier, left side of vision more than right side
- POH: unremarkable OU
- PMH: HTN, T2DM
- Med: lisinopril, metformin, Januvia, insulin
- Allergies: NKDA

Exam:

- VA cc: 20/20- OD, 20/25+2 OS
- Pupils: PERRL, (-)APD
- CVF: right inf depression OU?
- EOM: FROM OU
- Aseg: 1+ NS OU
- Pseg: normal, see photos
- IOP: 12 OD, 12 OS

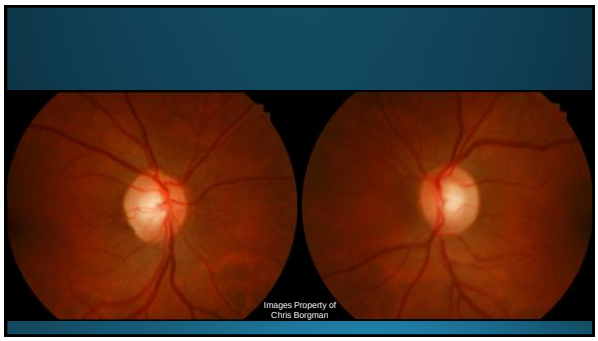
Images Property of
Chris Borgman

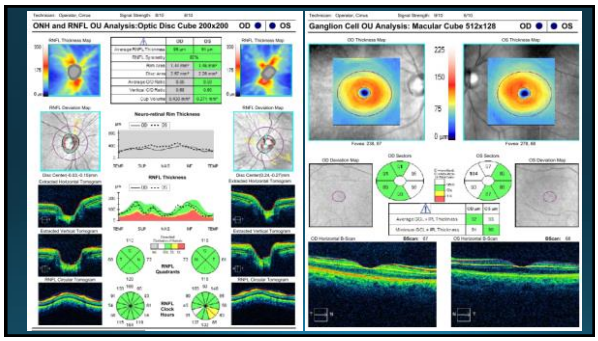
ONH and RNFL OU Analysis:Optic Disc Cube 200x200
Ganglion Cell OU Analysis: Macular Cube 512x128

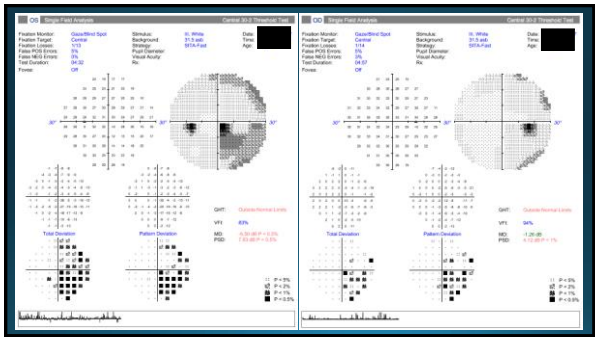

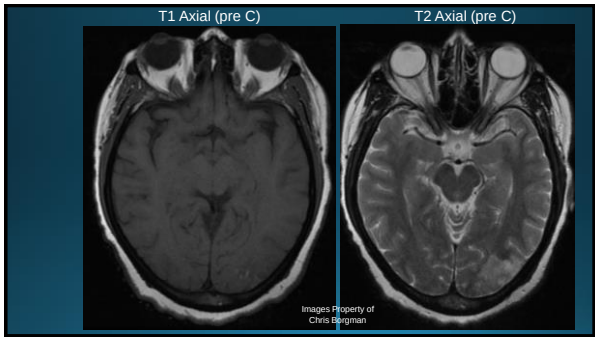
T1 Axial (pre C)
T2 Axial (pre C)
Images Property of
Chris Borgman

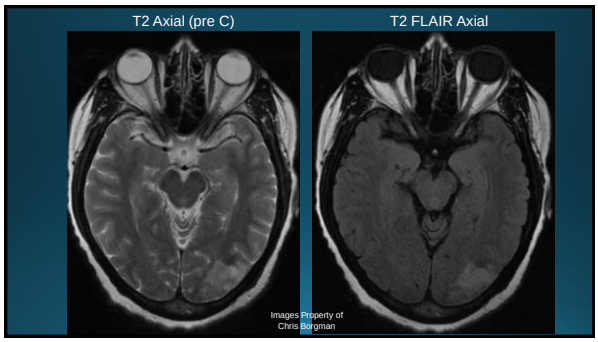
T2 Axial (pre C)
T2 FLAIR Axial
Images Property of
Chris Borgman

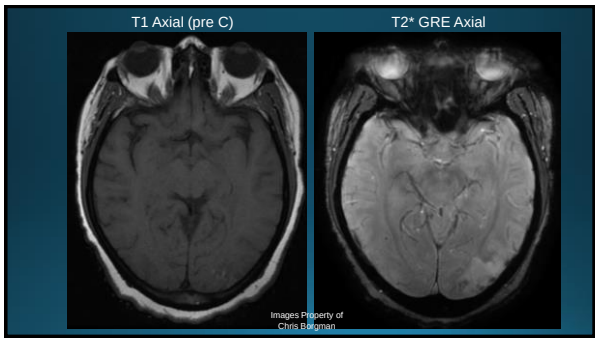
T1 Axial (pre C)
T2* GRE Axial
Images Property of
Chris Borgman

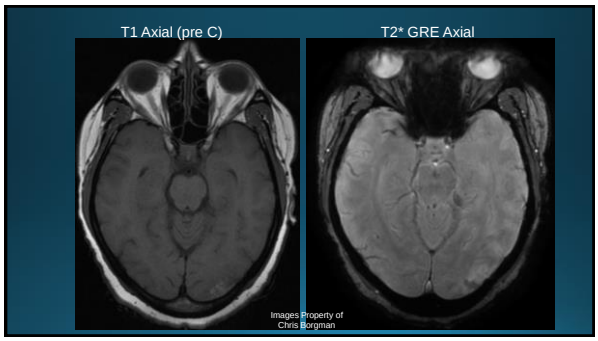

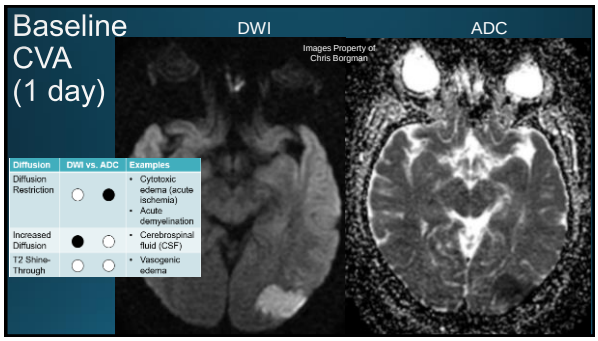

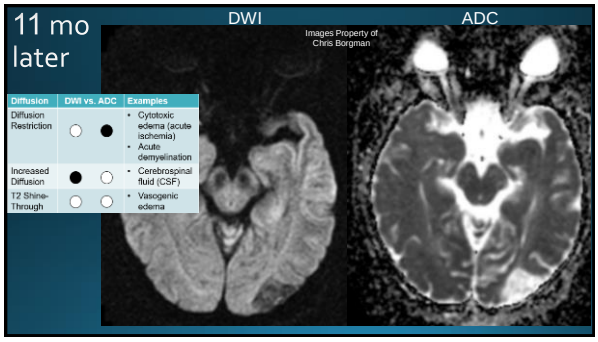

Case #3

Case

- 80 yo AAF
- CC: "I had a stroke and my neurologist wants to make sure my eyes are not involved"
- HPI: (+)CVA x 2 months, right sided weakness, (-)diplopia, (-)blurry vision
- POH: s/p phaco OU x 3 yrs
- PMH: T2DM, HTN
- Med: metformin, insulin, lisinopril, HCTZ
- Allergies: NKDA

Exam…

- VA sc: 20/20- OD, 20/20- OS
- Pupils: PERRL, (-)APD
- CVF: FTFC OU
- EOM: FROM OU
- Aseg: normal OU, clear PCIOL OU
- Pseg: normal OU
- IOP: 14 OD, 14 OS

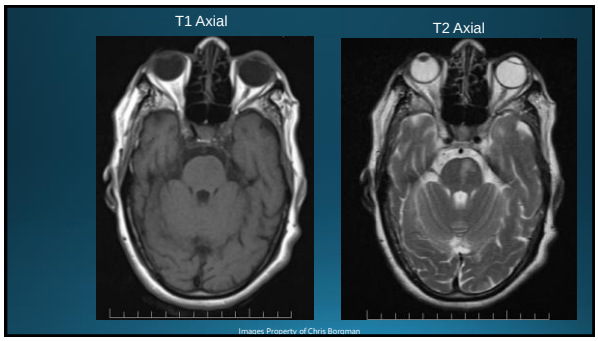

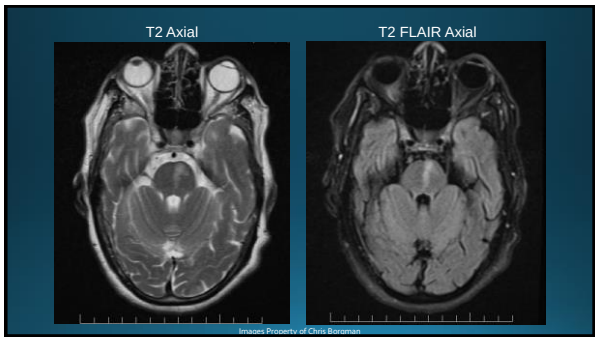

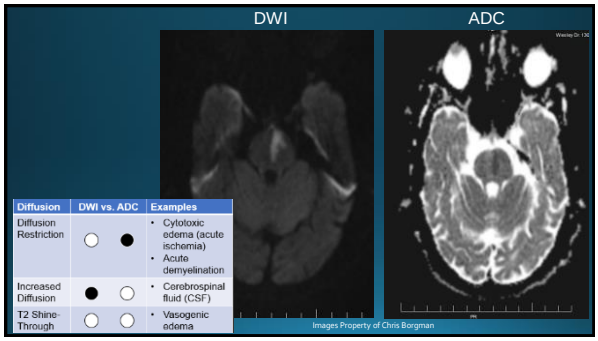

Diffusion	DWI vs. ADC		Examples
Diffusion Restriction	○	●	• Cytotoxic edema (acute ischemia) • Acute demyelination
Increased Diffusion	●	○	• Cerebrospinal fluid (CSF)
T2 Shine-Through	○	○	• Vasogenic edema

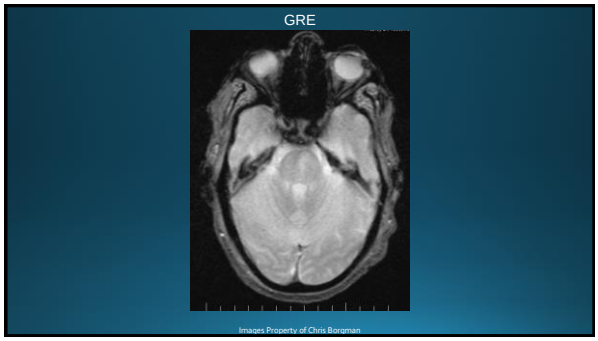

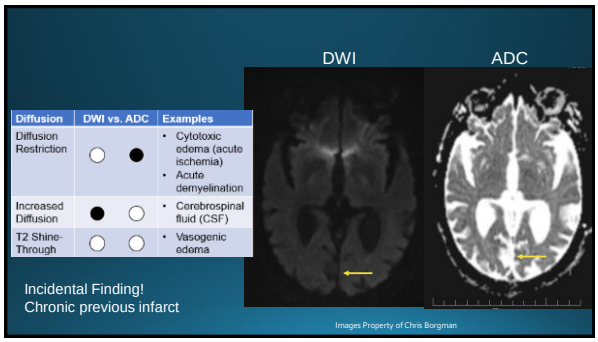

Diffusion	DWI vs. ADC		Examples
Diffusion Restriction	○	●	• Cytotoxic edema (acute ischemia) • Acute demyelination
Increased Diffusion	●	○	• Cerebrospinal fluid (CSF)
T2 Shine-Through	○	○	• Vasogenic edema

Final Thoughts

Know what potential diseases you are looking for based on the clinical presentation!

- Bone
- Foreign bodies
- Acute Stroke
- Metal (any kind)

} CT

- Soft tissue
- Acute stroke (after CT)
- Tumors

} MRI

When in doubt, call your local radiologist to get their professional opinion on what might be best based on your patient's specific situation!

Note On Collaboration: be specific when ordering scans!

- Relay as much clinical information as you can to help radiology locate your suspected pathology!
- Example: 34 yo WF with proptosis left eye, suspect TRO
- Order: "Orbit CT, no contrast, 1 mm sections, suspect thyroid eye disease (emphasis extraocular muscles)"
- Do not just order: "Orbit CT"
  - Specify what you are suspecting!

MRI: Ischemic vs. Hemorrhagic CVA

Sequence	Ischemic Stroke
T1	• CSF dark • Lesion dark or isointense
T2	• CSF bright • Lesion bright
T2 FLAIR	• CSF dark • Lesion bright
DWI	• Lesion bright
ADC	• Lesion dark
GRE/SWI	• Lesion isointense

Sequence	Hemorrhagic Stroke
T1	• CSF dark • Acute blood = bright
T2	• CSF bright • Lesion variable intensity
T2 FLAIR	• CSF dark • Blood variable intensity
DWI	• Lesion bright
ADC	• Lesion dark
GRE/SWI	• Lesion dark

Can CT miss something that MRI would find?

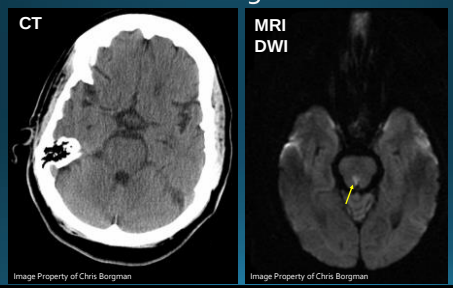

Can CT miss something that MRI would find?

CT MRI MRI

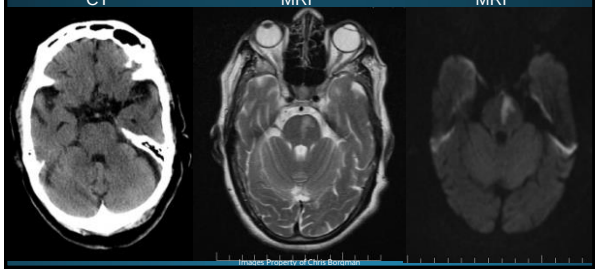

Can CT miss something that MRI would find?

CT MRI CT -5 days later

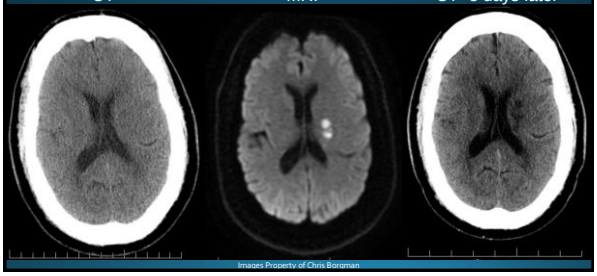

Can CT miss something that MRI would find?

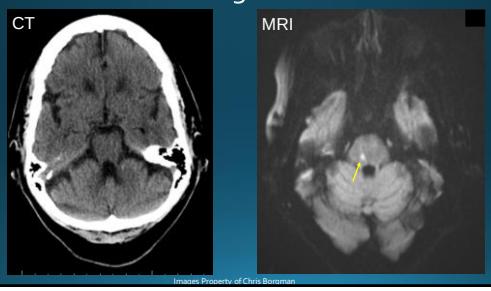

Images Property of Chris Borgman

Can CT miss something that MRI would find?

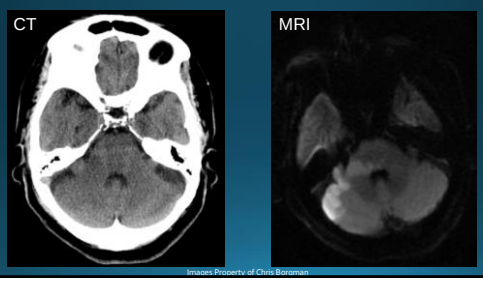

Images Property of Chris Borgman

Review:

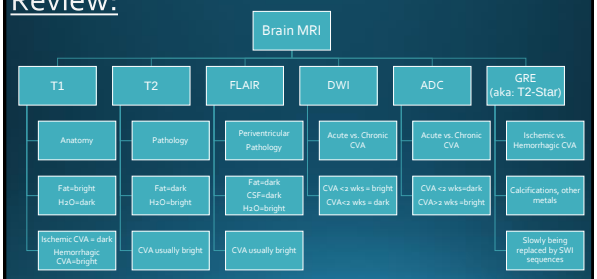

Bare Minimum Review: Important Points!

- CT = language of density!
- MRI = language of intensity!

- CT
  - Dark signal= ischemic stroke!
  - Bright signal = hemorrhagic stroke
  - When in doubt, measure HU!
- MRI
  - T2 shows most pathological processes related to CVA
  - DWI/ADC used in tandem to determine acute vs. chronic CVA

Remember: It's OK to call radiologist to discuss scans further if you need clarification!

Thank you!!!

Questions??
Accolades??

Email → cborgman@sco.edu

Complaints???



- Email → wmcgriff@sco.edu

SOUTHERN COLLEGE OF OPTOMETRY